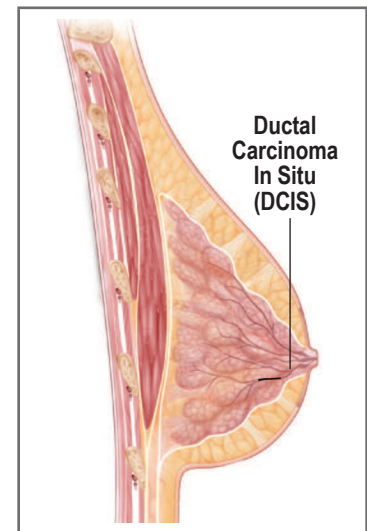

Ductal Carcinoma In Situ (DCIS) Female Patient

Definition of Terms:

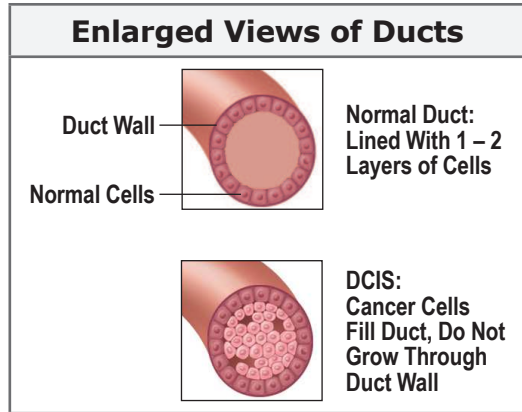
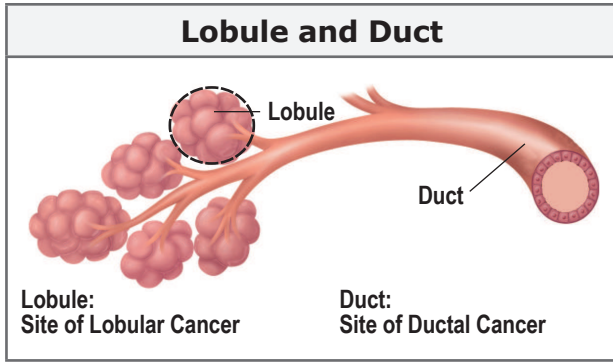
- **Benign** — Not cancerous; no threat to the body
- **Carcinoma** — Cancer cells that start in surface layers or lining of the ducts
- **In Situ** — In one contained area
- **Lumpectomy** — Removal of a lump and some surrounding tissues in the breast
- **Lymph Nodes** — Pea-like areas in the lymphatic system that act as filters of the body's cellular waste; lymph nodes under the arms filter waste from breast tissues
- **Malignant** — Cancerous; threat to the body
- **Mastectomy** — Removal of a breast by surgery
- **Metastasis** — Spread of cancer to other parts of the body
- **Microcalcifications** — Small areas of calcium deposits seen on mammography; may be related to a malignant or benign condition
- **Radiation Therapy** — Treatment with X-rays to kill remaining local cancer cells after surgery



Ductal carcinoma in situ is a pre-invasive cancer. This condition may have a potential for continuing to proliferate (grow) and become an invasive (grow through the duct walls) cancer. Excessive overgrowth of abnormal cells has filled the ducts in which the disease is located. Some authorities refer to the condition as “non-invasive cancer” and others as “pre-cancer.”

Most ductal carcinomas in situ are found by mammography when microcalcifications are observed in a clustered pattern or when they follow the shape of a duct. Usually, five or more calcifications in a very close area will be cause for the radiologist to study carefully the shape of the calcifications. If the shapes are suspicious, a biopsy, using needle localization or stereotactic technique, will be used to locate the findings and a biopsy will be performed. Sometimes a thickening or a soft mass will be found in the area of the breast.

When a biopsy of the area confirms ductal carcinoma in situ, you have a pre-invasive cancer that has potential to spread and threaten your life. Your physician will offer you several treatment options for carcinoma in situ, including: mastectomy, lumpectomy with radiation therapy, or occasionally lumpectomy without radiation therapy. A careful look at the extent of the disease, your age, family history and other factors will be considered in selecting the treatments appropriate for you.



Pathology Slides

Pathology Slide of Breast

Lobule →

↑ **Duct**

Image courtesy of www.breastpathology.info/images

Pathology Slide of DCIS

← **Cancer Cells**

← **Duct Wall**

Cancer cells are still within the duct and have not broken through the duct wall into surrounding tissues.

Image courtesy of www.pathologyoutlines.com